

Original Research Article

Histopathological Study of Hyperpigmented Skin Lesions in North Karnataka

Shilpa M Shetty¹, Vidhisha S Athanikar², US Dinesh³

¹Tutor, Department of Pathology, Shimoga Institute of Medical Sciences, Shimoga, Karnataka 577201, India. ²Professor and Head, Department of Pathology, SDM College of Medical Sciences and Hospital, Sattur, Dharwad, Karnataka 580009, India. ³Professor and Registrar, Department of Pathology, SDM University, Sattur, Dharwad, Karnataka 580009, India.

Abstract

Introduction: Hyperpigmentary skin disorders may be defined as increased pigmentation of the skin and/or mucous membranes to the extent that the patient concerned seeks medical advice. They have varied etiological factors and overlapping clinical features, thus necessitating the use of histopathology to aid the diagnosis. **Aims/Objectives:** To study the series of hyperpigmented skin lesions at our institute and to assess age, gender, site wise distribution of hyperpigmented skin lesions. **Materials and Method:** Study was conducted in the Department of Pathology, SDM College of Medical Sciences and Hospital, Dharwad, over a period of 5 years. Cases with hyperpigmented skin lesions seeking consultation in Dermatology and Surgery department were subjected to punch/ excisional biopsy after patient's consent. Tissue bits were subjected for processing and stained with H&E stain. Special stains were used whenever required. **Results:** 102 cases of hyperpigmented skin lesions were studied, out of which, 35 cases were non-neoplastic hyperpigmented lesions and 67 cases were neoplastic hyperpigmented lesions. In non-neoplastic lesions, 31 cases (88.57%) were inflammatory lesions with classical lichen planus being common (25.71%); others were 3 cases of metabolic lesions (8.57%) with 1 case each of macular amyloidosis, lichen amyloidosis, acanthosis nigricans and 1 case of infective lesion - Pityriasis versicolor (2.85%). In neoplastic lesions 89.55% cases were benign with Intradermal nevus (41.79%) being common and 10.44% were malignant with Malignant melanoma (7.46%) being common. **Conclusion:** Hyperpigmentary skin lesions are not uncommon and have overlapping clinical features. Histopathology plays a crucial role in diagnosing the lesions as well as differentiating melanocytic lesions from non-melanocytic lesions as both present with skin hyperpigmentation.

Keywords: Skin; Hyperpigmentation; Special stains; Lichen planus; Malignant melanoma; Histopathology.

Corresponding Author:

Shilpa M Shetty, Tutor, Department of Pathology, Shimoga Institute of Medical Sciences, Shimoga, Karnataka 577201, India.

E-mail: dhruvshetty010217@gmail.com

Received on 26.08.2019,

Accepted on 12.10.2019

How to cite this article:

Shilpa M Shetty, Vidhisha S Athanikar, US Dinesh. Histopathological Study of Hyperpigmented Skin Lesions in North Karnataka. Indian J Pathol Res Pract. 2019;8(6):755-762.

Introduction

Skin is the biggest organ in the body, accounting for about 15% of the complete body weight in adult beings. It exercises numerous essential protective tasks against environmental attacks that is made possible by a sophisticated framework, combining different tissues of ectodermal and mesodermal origin, arranged in three layers, including (from top to bottom) the epidermis (and its appendages), the dermis and the hypodermis.

Skin functions as an immune network and offers a distinctive defense against UV radiation through its pigments. Skin functions as a mirror through which the manifestations of intrinsic illnesses can be visualized.

Pigment issues are one of the most common causes of dermatological consultation. The color of the skin is extremely individual and the differences are regulated by various genes. Pigmentation disorders may lead from migration of melanocytes from the neural crest to the skin during embryogenesis, impaired transfer of melanocytes to keratinocytes, and modification of melanin synthesis.¹

Hyperpigmentary skin disorders may be defined as increased pigmentation of the skin and/or mucous membranes to the extent that the patient concerned seeks medical advice.² Hyperpigmentation may be caused by abnormality in dermis or epidermis; due to various factors like UV radiation, tanning, photoaging, drugs, chemicals, hormonal influences, inflammation, post-inflammatory hyperpigmentation causing melanin and non-melanin type of hyperpigmentation.³

In Asians, an important cosmetic complaint is hyperpigmentation.⁴ Psoriasis is a relapsing chronic inflammatory lesion affecting 1.5–3% of World's population.⁵ Lichen planus frequently affects Indian population.⁶ Melanocytic lesions are regarded important because though malignant melanoma accounts for 1% of skin cancers, but it is responsible for over 60% of cancer related deaths.⁷ Both Caucasians and Asians having acquired benign nevi hold a risk factor for cutaneous melanoma.⁸ Pigmented basal cell carcinoma is becoming increasingly common in Asian population with UV radiation being a preventable predisposing factor.⁹ In Indian scenario, pigmented skin lesions are frequent with special attention given to acquired hyperpigmentation as it is difficult to diagnose and treat satisfactorily. North Karnataka being one of the tropical area of the country, people have to face intense summers. Thus, because of

increased exposure to sun and sweating, people are predisposed to hyperpigmentation and fungal infection. Following factors necessitates the use of histopathology for an appropriate diagnosis which are : increasing incidence and complexity in understanding of hyperpigmented skin lesions, overlapping clinical features, mode of presentation for both non-melanocytic and melanocytic lesions is hyperpigmentation and presence of many benign and malignant mimickers of malignant melanoma.

Materials and Methods

Study was conducted over a period of 5 years in the Department of Pathology, SDM College of Medical Sciences and Hospital, Dharwad. Patients with hyperpigmented skin lesions, who are taking consultation in the Department of Dermatology and Surgery with representative biopsy specimen sent to the Department of Pathology in SDMCMSH were studied. The biopsy taken was received by Pathology department in bottles containing 10% buffered formalin and was fixed in it for 15–24 hours. Following day after a detailed gross examination, sections were given. The bits were placed in plastic cassettes and taken through paraffin processing for 18–21 hours, followed by routine haematoxylin and eosin staining. Slides and blocks were collected for review. Detailed histopathological examination of the samples was conducted and assessment was done based on age and gender of the patient and site of lesion. After slide review final histopathological diagnosis was given. Special stains done whenever required. Masson Fontana stain was used for melanin to differentiate between dermal and epidermal Hyperpigmentation, Periodic Acid Schiff stain (PAS) was used to detect fungal spores and Congo red stain was used to identify amyloid deposits. Ethical clearance has been obtained from Institutional ethical committee.

Results

The study was conducted for a duration of 5 years from June 1st 2009 to June 1st 2014. Total of 102 cases of hyperpigmented skin lesions were studied. Non-neoplastic lesions (35 cases, 34.31%) were sub-divided into inflammatory (88.57%), infective (2.85%) and metabolic lesions (8.57%). Neoplastic lesions (67 cases, 65.68%) were further subdivided into benign (89.55%) and malignant category (10.44%). In non-neoplastic lesions commonest lesion was lichen planus (25.71%), followed by

morphea (14.28%) and scleroderma (11.42%). In neoplastic lesions, commonest benign neoplasm was intradermal nevus (41.79%) followed by epidermal nevus (10.44%). In malignant lesions, commonest was malignant melanoma (7.46%), followed by pigmented basal cell carcinoma (2.98%) which is mentioned in Table 1.

Commonest age group affected in non-neoplastic lesions and benign neoplasms was 21–30 years

(25.71% and 29.85% respectively) whereas in malignant neoplasms it was 51–60 years (4.77%) which is mentioned in Table 2. Graph 1 shows female preponderance was found in non-neoplastic lesions (57.14%) as well as neoplastic lesions (70.14%).

Table 3 shows commonest site of involvement in non-neoplastic lesions and malignant neoplasm was extremities (37.14% and 8.95% respectively),

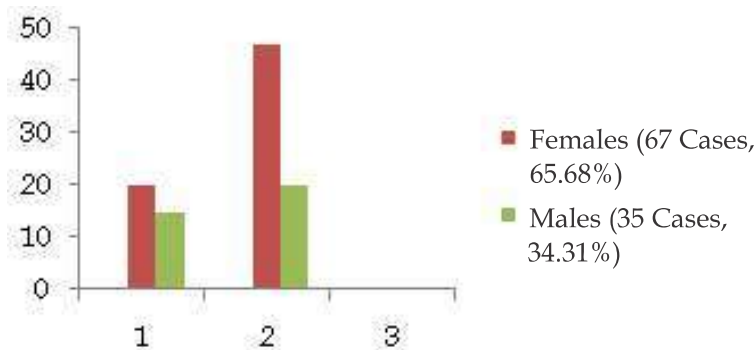
Table 1: Distribution of lesions

Sl. No.	Lesions	No. of cases	Specific category %
(I)	Non-neoplastic lesions	35	100
(a)	Inflammatory lesions	31	88.57
01.	Lichen planus	09	25.71
02.	Hypertrophic lichen planus	02	5.71
03.	Lichen planus pigmentosus	01	2.85
04.	Lichenoid dermatitis	01	2.85
05.	Eczematous dermatitis	01	2.85
06.	Discoid lupus erythematosus	01	2.85
07.	Prurigo simplex	01	2.85
08.	Morphea	05	14.28
09.	Scleroderma	04	11.42
10.	Lichen simplex chronicus	03	8.57
11.	Post-inflammatory hyperpigmentation	03	8.57
(b)	Infective lesion - pityriasis versicolor	01	2.85
(c)	Metabolic lesions	03	8.57
01.	Macular amyloidosis	01	2.85
02.	Lichen amyloidosis	01	2.85
03.	Acanthosis nigricans	01	2.85
(II)	Neoplastic lesions	67	100
(a)	Benign	60	89.55
01.	Lentigo simplex	02	2.98
02.	Beckers nevus	01	1.49
03.	Intradermal nevus	28	41.79
04.	Epidermal nevus	07	10.44
05.	Compound nevus	03	4.47
06.	Congenital melanocytic nevus	01	1.49
07.	Congenital compound nevus	03	4.47
08.	Osteonevus of nanta	02	2.98
09.	Pigmented spindle cell nevus	01	1.49
10.	Spitz nevus	01	1.49
11.	Seborrheic keratosis	05	7.46
12.	Pigmented seborrheic keratosis	03	4.47
13.	Acanthotic seborrheic keratosis	01	1.49
14.	Urticaria pigmentosa maculopapular adult type	01	1.49
15.	Telangiectasia macularis eruptiva perstans	01	1.49
(b)	Malignant	07	10.44
01.	Malignant melanoma	05	7.46
02.	Pigmented basal cell carcinoma	02	2.98
	Total no. of cases	102	100

Table 2: Age wise distribution of lesions.

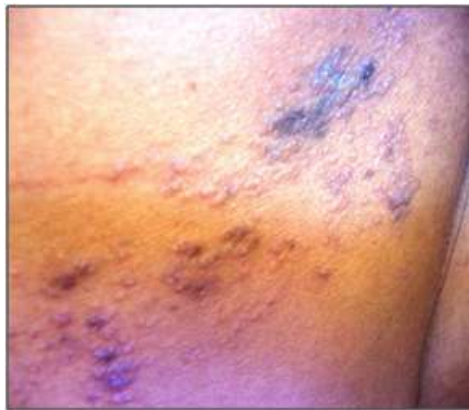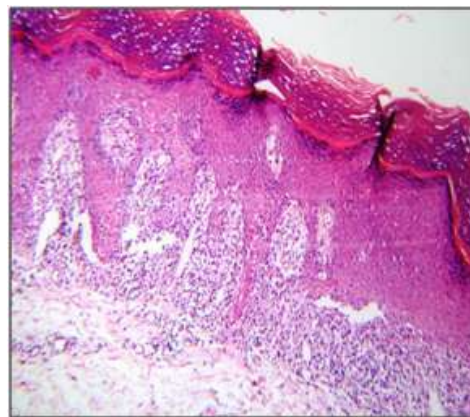
Age in years	Non-neoplastic lesions (35 cases)	% of non-neoplastic cases	Neoplastic lesions (67 cases)		% of Neoplastic cases
			B (%)	M (%)	
Birth-10	-	-	7 (10.44)	-	10.44
11-20	5	14.28	15 (22.38)	-	22.38
21-30	9	25.71	20 (29.85)	-	29.85
31-40	7	20	7 (10.44)	-	10.44
41-50	6	17.14	-	2 (2.98)	2.98
51-60	5	14.28	4 (5.97)	3 (4.47)	10.44
61-70	3	8.57	3 (4.47)	2 (2.98)	7.46
71-80	-	-	3 (4.47)	-	4.47
81-90	-	-	1 (1.49)	-	1.49

B - Benign, M - Malignant

**Graph 1:** Gender wise distribution of lesions.**Table 3:** Site wise distribution of lesions.

Site of lesion	Non-neoplastic lesions (35 cases) with %	Neoplastic lesions (67cases)	
		Benign (60 cases) with %	Malignant (7 cases) with %
Head and neck	5 (14.28)	42 (62.68)	1 (1.49)
Extremities	13 (37.14)	6 (8.95)	6 (8.95)
Trunk	5 (14.28)	12 (17.91)	-
Anogenital region	2 (5.71)	-	-
All over the body	10 (28.57)	-	-

Lichen Planus

**Fig. 1a:** Clinical photograph showing violaceous papules.**Fig. 1b:** H&E, 4x - Hyperkeratosis, saw tooth rete ridges, interface lymphocytic infiltrate.

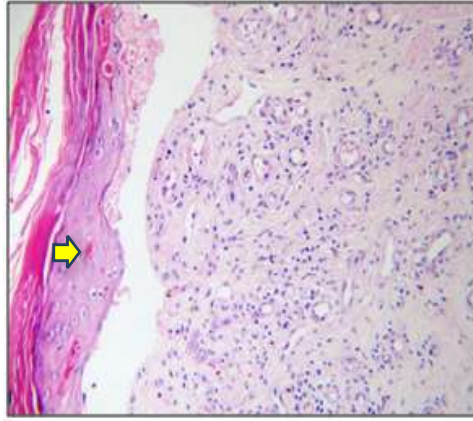


Fig. 1c. H&E, 10x - Max Joseph space and Civatte bodies (arrow).

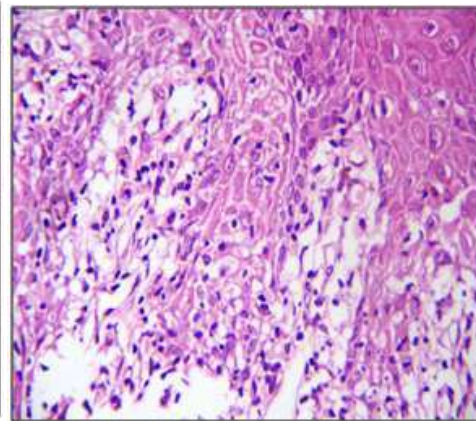


Fig.1d. H&E, 40x - Vacuolar degeneration of basal cells.

Acanthosis Nigricans

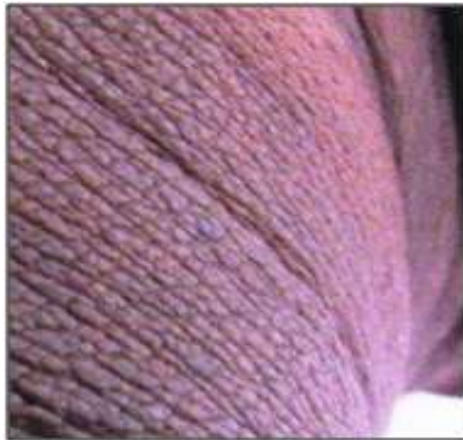

Fig. 2a. Clinical photograph - velvety plaque on neck.

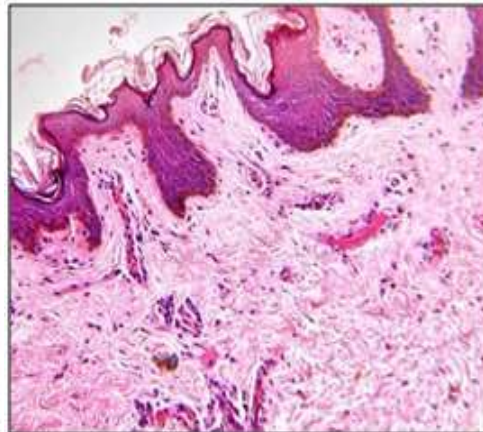


Fig. 2b. H&E, 4x - hyperkeratosis, acanthosis, papillomatosis, increased basal cell layer pigmentation.

Pityriasis Versicolor

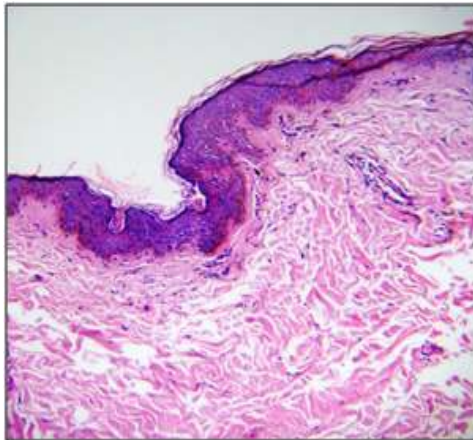


Fig. 3a. H&E, 4x - Fungal spores in Stratum corneum, increased basal cell layer pigmentation.

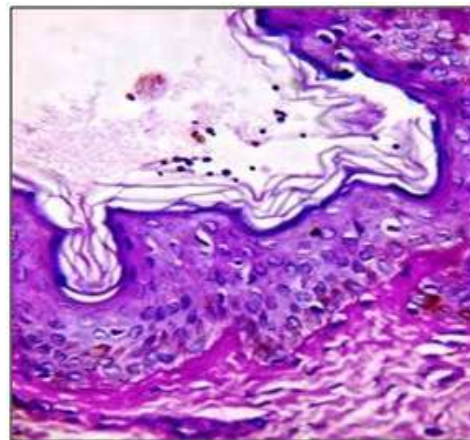


Fig. 3b. PAS, 40x - fungal spores in Stratum corneum.

Spitz Nevus

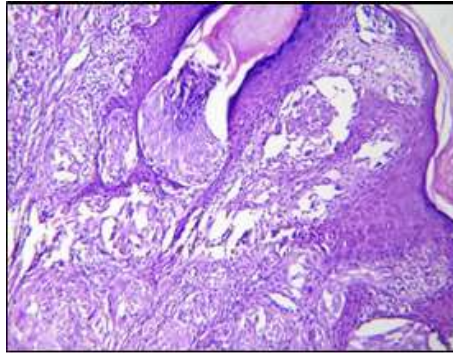


Fig. 4a. H&E, 4x - Junctional activity with nevus cells in dermis.

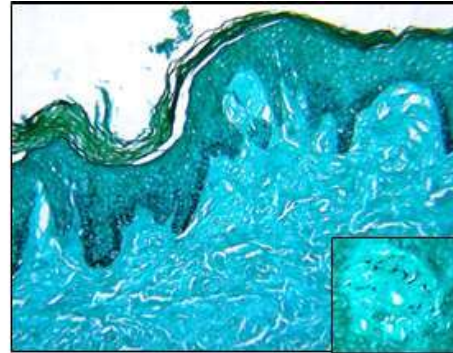


Fig. 4b. Masson-Fontana, 4x - increased basal cell layer pigmentation. **Inset Masson-Fontana 40x** - intracytoplasmic melanin in nevus cells.

Malignant Melanoma

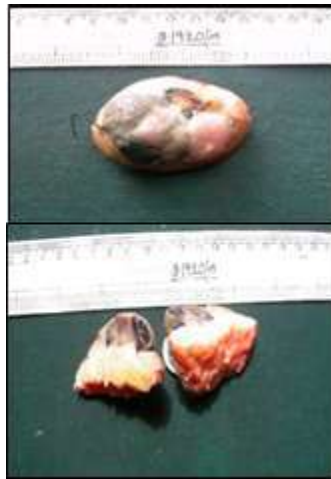

Fig. 5a. Gross - black nodule on skin surface. Cut section of nodule - homogenous blackish areas.

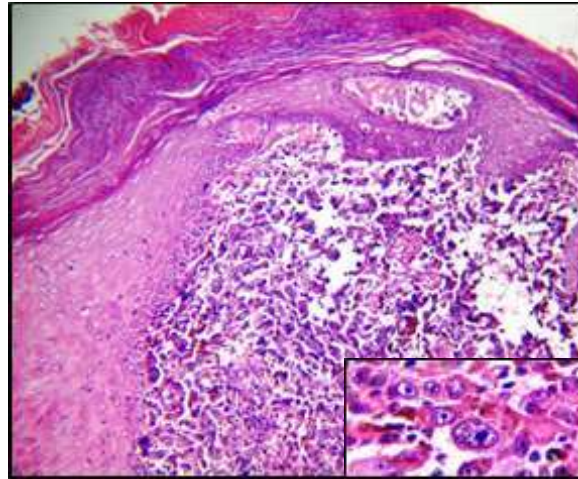


Fig. 5b. H&E, 10x - Junctional activity, melanoma cells in dermis. **Inset H&E, 40x** - melanoma cells in dermis.

whereas in benign neoplasm 62.68% cases showed involvement of head and neck region.

Discussion

It is difficult to diagnose hyperpigmented skin lesions as they have wide variety of etiologic factors. In Asians, skin hyperpigmentation is the commonest cosmetic problem thus increasing the need for correct diagnosis and appropriate therapeutic strategy. In the present study, out of 35 non-neoplastic lesions, 31 cases (88.57%) belonged to inflammatory category in which classical type lichen planus (9/35 cases, 25.71%) was the commonest lesion encountered. Clinically, the age

group of presentation was 11 to 70years with M:F ratio of 1:1.25. They had multiple violaceous papules with or without pruritus on trunk, upper limbs, anogenital region, lower limbs which is showed in Fig. 1a. Histopathology showed hyperkeratosis, basal cell vacuolar degeneration, band like lymphocytic infiltrate in dermo-epidermal junction, perivascular lymphocytic infiltrate and melanin incontinence; other features seen were acanthosis, hypergranulosis, saw tooth rete ridges, Civatte bodies and Max Joseph space which is showed in Fig. 1b, 1c, 1d. Histopathological examination of Pityriasis versicolor revealed epidermis with increased basal cell layer pigmentation, stratum corneum showed basophilic fungal spores further demonstrated by Periodic acid Schiff stain and

dermis showed perivascular inflammatory infiltrate composed of lymphocytes, plasma cells, histiocytes and also melanin incontinence as seen in Fig. 3a, 3b. A 17 years female presented with solitary brown coloured velvety plaque over neck, which on histopathology showed hyperkeratosis, acanthosis, orthokeratosis, papillomatosis, increased basal cell layer pigmentation of epidermis and dermis showed pigment incontinence, sparse lymphocytic infiltrate in Fig. 2a, 2b. Age wise distribution of non-neoplastic lesions showed majority of patients, i.e. 9/35 (25.71%) belonging to the age group of 21 years to 30 years. Laishram R S *et al.*¹⁰ and Goyal K *et al.*¹¹ in their study showed similar age group to be affected, involving 57.14% and 28% of cases respectively. Female preponderance was seen in the present study with 20/35 (57.14%) female patients and female to male ratio (F:M) being 6:1. Laishram R S *et al.*⁹ and Tienthavorn T *et al.*¹², also showed female predominance with F:M ratio of 6:1 and 5.14:1 respectively. In present study, commonest non-neoplastic lesion was Lichen planus and its variants 12/35 (34.28%). Study done by Mruthyunjayappa S *et al.*¹² and Jayker S S *et al.*¹³, also found lichen planus and its variants to be the commonest non-neoplastic lesion with 55% and 20% of cases respectively. Histopathological examination of Spitz nevus in Fig. 4a, 4b revealed junctional activity and theques of nevus cells in the basal layer with dermis showing melanin incontinence and nevus cells arranged in nests, cords; deep dermis showed maturation of nevus cells giving an appearance of rain drops; artifactual clefting was seen around the nests of nevus cell. In malignant neoplastic lesions there were 5 cases of malignant melanoma which is shown in Fig. 5a, 5b. Further diagnosed as : 2 cases of Clarks level IV; 1 case of Clarks level V; 1 case of nodular malignant melanoma, Clarks level V and 1 case of nodular spindle cell melanoma, Clarks level IV. Other malignant lesion encountered were 2 cases of pigmented basal cell carcinoma. In the present study, out of 67 neoplastic cases, benign lesion 20/60 (33.33%) cases presented in the age group of 21 years – 30 years. Suvernakar S V *et al.*⁶ and Laishram R S *et al.*⁹, in their study found age group of 21 years – 40 years and 21 years – 30 years respectively to have been affected by benign lesions. Age at presentation in malignant lesions 3/7 (42.85%) cases was 51 years – 60 years, which correlates with study done by Laishram R S *et al.*⁹ Female preponderance seen in present study (F:M – 2.33:1) for neoplastic lesions correlated with study done by Laishram R S *et al.*⁹ (F:M – 6.5:1) and

Suvernakar S V *et al.*⁶ (F:M – 1.1:1). Commonest site of involvement in neoplastic lesions was head and neck region affecting 64.17% of cases. Suvernakar S V *et al.*⁶ in their study found head and neck region (63.64%) to be the commonest site of involvement for neoplastic lesions. Commonest benign neoplasm in present study was intradermal nevus 28/60 (46.66%). Parvathi M *et al.*¹⁴ and Laishram R S *et al.*⁹ in their study also found that intradermal nevus was the commonest benign neoplasm with 38.63% and 64.53% of cases respectively. Malignant melanoma 05/07 (71.42%) was the commonest malignant neoplasm in the present study which correlated well with a study done by Laishram R S *et al.*¹⁰, also showing malignant melanoma 18/25 (72%) as the commonest malignant neoplasm. Five pigmented lesions were clinically over-diagnosed as Malignant melanoma and on histopathology these cases were diagnosed as one case each of acanthotic seborrheic keratosis, seborrheic keratosis, intradermal nevus, pigmented spindle cell nevus and lichen simplex chronicus. One case of pigmented basal cell carcinoma was misdiagnosed clinically as malignant melanoma. Two cases of malignant melanoma were clinically misdiagnosed as squamous cell carcinoma and soft tissue sarcoma.

Conclusion

As hyperpigmentary skin disorder is an important cosmetic complaint in Asians; it has drawn the attention of many pathologists and formed a topic of interest for detailed study in India. But, there was a paucity of literature in this part of North Karnataka with increasing incidence of hyperpigmentary skin lesions, which led us to take up the present study with the aim of studying the distribution pattern of various hyperpigmentary skin lesions. In the present study, only 102 cases underwent biopsy and histopathological examination in the duration of 5 years. But still, many key points were observed which did correlate with other studies and showed that hyperpigmentary skin disorders have a predilection for females, it is predominantly located over the sun exposed areas indicating role of ultraviolet radiation in its pathogenesis, intradermal nevus is commonly seen with increasing age commonly occurring in the age group of 21 to 30 years and malignant melanoma has many benign as well as malignant mimickers. Hence, more and more hyperpigmentary skin lesions should be subjected for histopathological examination for a better diagnostic approach and treatment strategies.

References

1. Dutta AK, Datta PK, Dhar S. Hyperpigmentary Disorders. In Valia R G, ValiaA R. IADVL Textbook and Atlas of Dermatology vol. 1, 2nd edition. Mumbai:Bhalani, 2003.p.760.
2. Costin GE, Hearing VJ. Human skin pigmentation: melanocytes modulate skin color in response to stress. *FASEB J.* 2007;21:976-94.
3. Kurita M, Kato H, Yoshimura K. A therapeutic strategy based on histological assessment of hyperpigmented skin lesions in Asians. *Journal of Plastic, Reconstructive and Aesthetic Surgery.* 2009;62:955-63.
4. Mehta S, Singal A, Singh N, *et al.* A study of clinico histopathological correlation in patients of psoriasis and psoriasiform dermatitis. *Indian J Dermatol Venereol Leprol.* 2009;75:100.
5. Kanwar A J, Dogra S, Handa S, *et al.* A study of 124 Indian patients with lichen planus pigmentosus. *Clin Exp Dermatol.* 2003 Sep;28(5):481-5.
6. Suvernakar SV, Harwani SR, Deshpande SA. Clinicopathological Study of Pigmented Skin Lesions. *IOSR Journal of Dental and Medical Sciences.* 2014 May;13(5):70-73.
7. Leung KM, Chan KW. Pattern of pigmented skin tumours seen by private practitioners in Hong Kong. *Hong Kong J. Dermatol. Venereol.* 2007;15:113-117.
8. Deepdarshan K, Mallikarjun M, Abdu NN. Pigmented Basal Cell Carcinoma: A Clinical Variant, Report of Two Cases. *Journal of Clinical and Diagnostic Research.* 2013 Dec;7(12): 3010-3011.
9. Laishram RS, Myrthong BG, Laishram S, *et al.* Pigmented skin lesions: are they all of melanocytic origin? A histopathological perspective. *Journal of Pakistan Association of Dermatologists.* 2013;23(3):284-288.
10. Goyal K, Chahal KS, Malhotra SK. To study the clinicopathological correlation of common pigmentary disorders of skin. *International journal of science and research.* 2018 Apr;7(4): 1448-1452.
11. Tienthavorn T, Tresukosol P, Sudtikoonaseth P. Patch testing and Histopathology in Thai patients with hyperpigmentation due to Erythema dyschromicum perstans, Lichen planus pigmentosus, and Pigmented contact dermatitis. *Asian Pac J Allergy Immunol.* 2014;32:185-92.
12. Mruthyunjayappa S, Mahantappa H, Gopal MG, Venugopal SB. A study of spectrum of histopathological features in patients presenting with hyperpigmented skin lesions. *Archives of medicine and Health sciences.* 2018 Jul-Dec;4(2):189-95.
13. Jayker SS, Anantharaj J, Surhonne SP, *et al.* Histopathological spectrum of hyperpigmented lesions of skin. *J. Evolution Med. Dent. Sci.* 2016; 5(34):1913-16.
14. Parvathi M, Balaji C, Lekha D, *et al.* A clinicopathological study of pigmented cutaneous lesions: a one year prospective study in a tertiary care hospital. *International Journal of research in medical sciences.* 2017 Dec;5(12):5316-21.

